


Aural haematoma in dogs

Aural haematoma (often colloquially called 'blood blister of the ear') is a common and distressing condition for dogs. An aural haematoma describes a build-up of bloody liquid within the ear flap.

This study aimed to explore the frequency of aural haematoma in UK dogs and identify breeds and types of ear flap that were most affected.



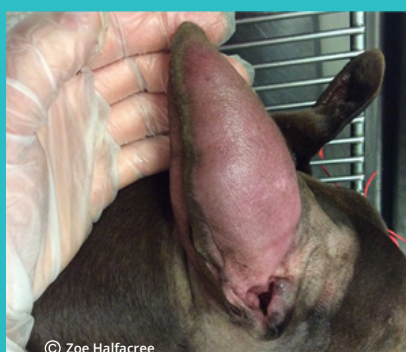Number of dogs in study

905,554

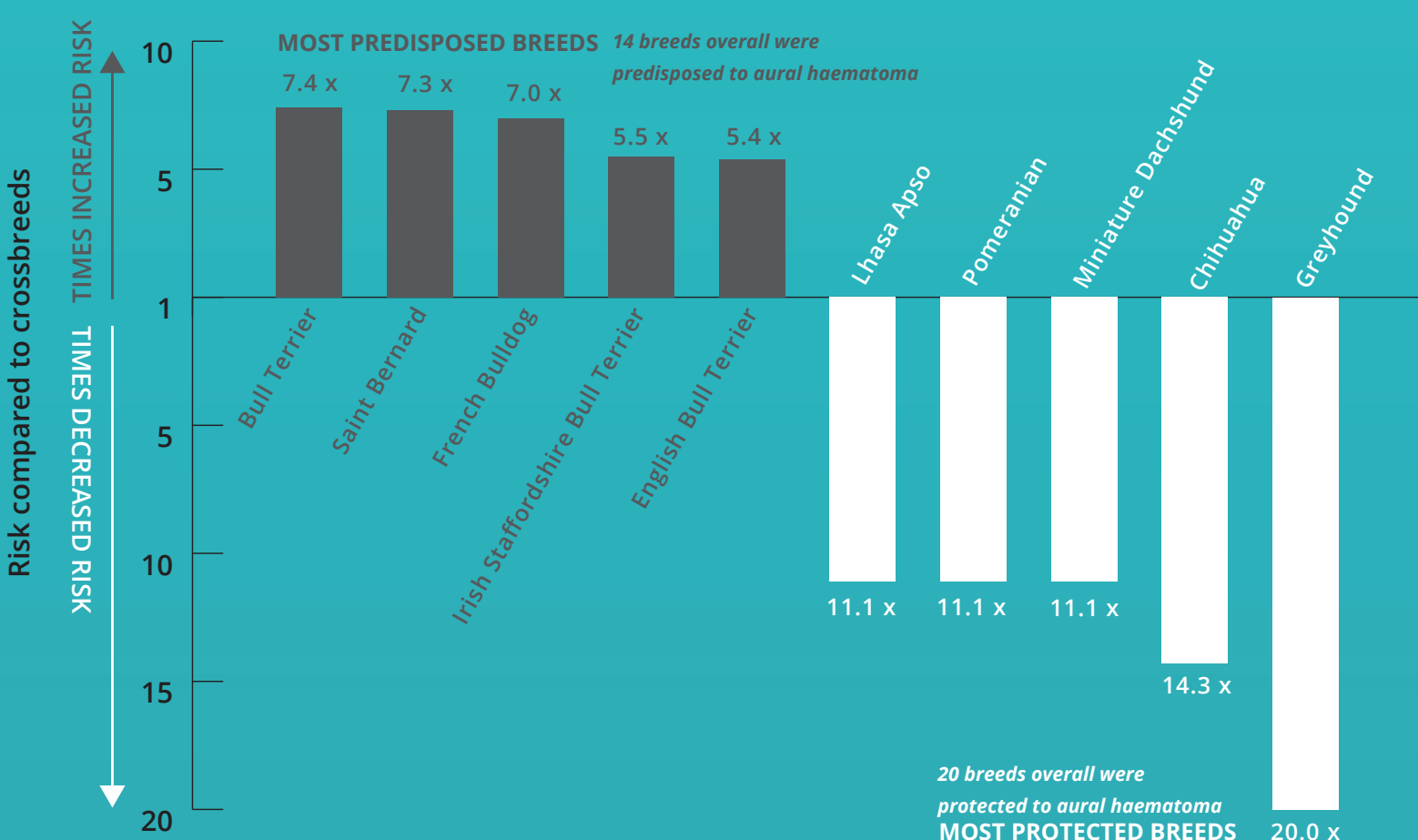
Proportion of dogs with aural haematoma each year

1 in 400 (0.25%)

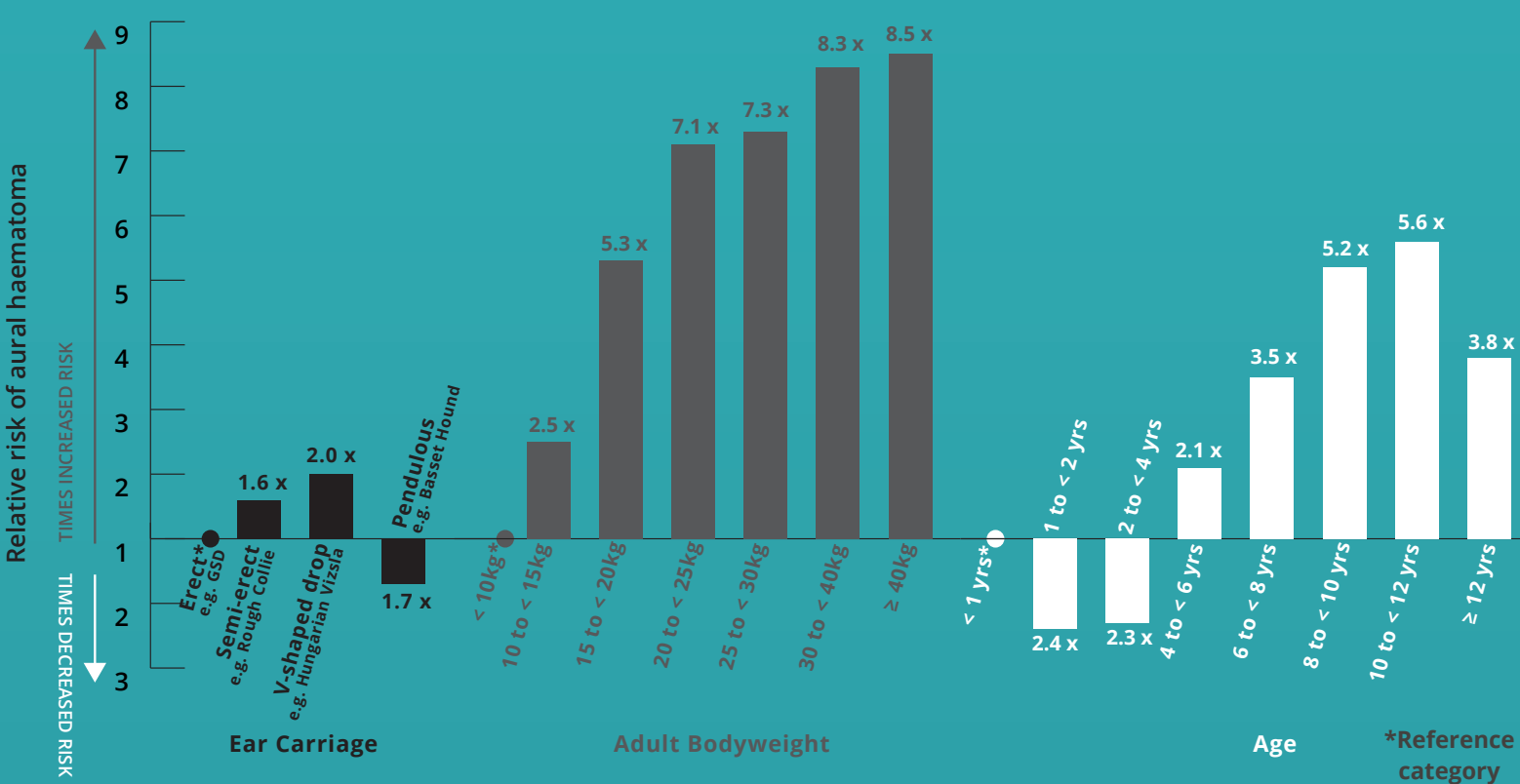
What does an aural haematoma look like?



Does the risk of aural haematoma vary by breed?



Other factors predisposing to aural haematoma



CONCLUSIONS:

Aural haematoma is not uncommon in dogs. Owners should check their dog's ears regularly and seek veterinary advice if concerned.

VetCompass proposes a novel cartilage-folding hypothesis for aural haematoma. Repeated folding of the ear flap along the line of cartilage fold within certain types of ear carriage is proposed to lead to chronic damage and weakness along this fold line. This may eventually trigger a bleed into the ear flap, resulting in an aural haematoma.

Owners of high-risk breeds and ear types should be particularly aware of indicators of aural haematoma e.g. head shaking and a swollen, droopy ear flap.

CLICK TO READ

O'Neill et al. (2021) "Reporting the epidemiology of aural haematoma in dogs and proposing a novel aetiopathogenetic pathway" Scientific Reports

RVC VetCompass <https://www.rvc.ac.uk/vetcompass> carries out welfare research based on anonymised clinical information shared from over 30% of UK veterinary practices. We are very grateful to the owners and veterinary professionals who contribute to VetCompass research.